

CASE PRESENTATION

Functional assessment in left ventricular non-compaction cardiomyopathy in multimodality imaging era might improve the definition

Ionela Simona Visoiu¹, Roxana Cristina Rimbas^{1,2}, Loredana Gheorghiu^{1,2}, Ruxandra Dragoi Galrinho Antunes Guerra^{1,2}, Alina Ioana Nicula^{1,3}, Dragos Vinereanu^{1,2}

Abstract: Left ventricular non-compaction (LVNC) is an increasingly recognized phenotype. The current definition of the LVNC does not mention LV dysfunction as an absolute criterion in addition to morphological criteria. LV dilatation and decreased LV ejection fraction (LVEF) are often late manifestations of the disease and correlate with the occurrence of cardiovascular complications. However, to define LVNC as a cardiomyopathy, functional criteria must be fulfilled, in addition to the morphological ones. Multimodality imaging, such as myocardial deformation and myocardial work analysis derived from speckle tracking echocardiography (STE), in combination with cardiac magnetic resonance (CMR) might improve diagnosis and characterization of non-compaction, exposing earlier signs of LV systolic dysfunction. We present two comparative cases of LVNC in order to highlight the idea of subclinical dysfunction even in apparently benign forms with preserved LVEF, and also the importance of multimodality imaging approach.

Keywords: non-compaction, cardiomyopathy, multimodality imaging, myocardial work, fibrosis.

Rezumat: Non-compactarea de ventriculul stâng (NCVS) este un fenotip din ce în ce mai recunoscut. Definiția actuală a NCVS nu menționează disfuncția VS ca un criteriu absolut, adițional criteriilor morfologice. Dilatarea VS și scăderea fracției de ejeție a VS (FEVS) sunt adesea manifestări tardive ale bolii, ce se corelează cu apariția complicațiilor cardiovasculare. Pentru a defini NCVS ca și cardiomiopatie, trebuie să fie îndeplinite și criterii funcționale, adițional celor morfologice. Imagistica multimodală, ce include analiza deformării miocardice și a lucrului mecanic cardiac derivată din ecocardiografia speckle tracking (STE), în combinație cu rezonanța magnetică cardiacă (RMC) ar putea îmbunătăți diagnosticul și caracterizarea non-compactării, demascând semne precocce ale disfuncției sistolice de VS. Prezentăm două cazuri comparative de NCVS pentru a evidenția ideea prezenței disfuncției subclinice chiar și în forme aparent benigne cu FEVS prezervată și, de asemenea, importanța abordării imagistice multimodale.

Cuvinte cheie: non-compactare, cardiomiopatie, imagistică multimodală, lucru mecanic cardiac, fibroză.

INTRODUCTION

LVNC is a cardiac phenotype characterized by a bilayered myocardium, consisting of a thin, compacted epicardial layer (*compacted myocardium* - CM) and a much thicker, non-compacted endocardial layer (*non-compacted myocardium* - NCM), with trabeculations and deep intertrabecular recesses¹. It was classified as a distinct primary genetic cardiomyopathy by the American Heart Association in 2006, and as an unclassified cardiomyopathy by the European Heart Association in 2008^{1,2}.

According to last guidelines, cardiomyopathies are defined by structural and functional abnormalities of the ventricular myocardium that are unexplained by flow limiting coronary artery disease or abnormal loading conditions². However, the current definition of LVNC does not mention the LV dysfunction as an absolute criterion, but only non-standardized morphological criteria³⁻⁷, thus creating multiple controversies. Chin et al.³ defined LVNC by echocardiography when CM/(NCM + CM) is ≤ 0.5 , assessed at end-diastole on short-axis parasternal views. Jenni et al. redefined the

criteria as a NCM/CM ratio >2 at end-systole on short axis parasternal view⁴. The trabecular anatomy represents a true cardiac fingerprint⁸, which can vary greatly from one ethnic group to another, from women to men, from children to adults. In this line, the echocardiographic criteria were later refined by Stollberger et al.⁵. They proposed to diagnose LVNC considering the presence of >3 trabeculations along the LV endocardial border visible in end-diastole, distinct from the papillary muscles, false tendons, and aberrant muscle bands, which move synchronously with the CM. According to Stollberger, the perfusion of intertrabecular spaces from the ventricular cavity is better visualized at end-diastole, while the bilayered myocardium is better assessed at end-systole. Regarding the CMR, two main different criteria were proposed, by Petersen et al.⁶, as a NCM/CM ratio of ≥ 2.3 in end-diastole on long axis images, at a site with the most prominent trabeculations, and Jacquier et al.⁷, as the presence of a NCM mass greater than 20% of the global LV mass in a short axis end-diastolic image.

Moreover, with increasing awareness and advanced imaging techniques, two major forms have been identified: LVNC with reduced LVEF and LVNC with preserved LVEF^{9,10}, the functional impact of NC being questionable.

Myocardial work (MW) by STE, a new parameter that takes into account deformation as well as after-load through interpretation of strain in relation to dynamic non-invasive LV pressure¹¹, might help identifying the functional implications in LVNC. It has already shown incremental value to myocardial deformation to identify the responders to cardiac resynchronization therapy¹², acute coronary occlusion in patients with non-ST-elevation acute coronary syndrome¹³, and prognostic value in cardiac amyloidosis¹⁴. MW related indices consist of myocardial constructive work (CW), as MW performed during LV shortening in systole and LV lengthening during the isovolumic relaxation, contributing to LV ejection during systole, myocardial wasted work (WW), as MW performed during LV lengthening in systole and shortening during the isovolumic relaxation phase that does not contribute to LV ejection, and MW efficiency (MWE), calculated as the ratio between CW/(CW + WW)¹¹.

In order to evaluate the functional implication of NC, we present a comparative multimodality imaging assessment of two cases with a clear diagnosis of LVNC and heart failure (HF) with both preserved and reduced ejection fraction.

CASE I

A 56-year-old woman with history of hypertension and hypothyroidism presented with progressively low exertional dyspnea in the past 2 years, associated with palpitations. She has a history of sudden deaths in her family, a niece at 23 and a nephew at 40. On clinical examination, she had bradycardia and increased blood pressure of 180/100 mmHg. ECG showed inferior atrial rhythm, left anterior fascicular block, with fragmented QRS in inferior leads and slightly increased QTc interval of 458 ms. NTproBNP was elevated at 349 pg/ml. 24-hour Holter ECG monitoring revealed background sinus bradycardia, with multiple supraventricular extrasystoles (6449/24h) and rare isolated premature ventricular complexes (PVC) (53 /24h).

Transthoracic echocardiography (TTE) showed a non-dilated left ventricle (end-diastolic volume = 55 ml/m²), LVEF of 60% and grade I diastolic dysfunction, with prominent trabeculations of the LV myocardium (Figure 1A, Video 1), fulfilling both Stollberger and Jenni criteria for LVNC (NCM/CM ratio=3). She had no significant valvulopathies. CMR confirmed the diagnosis of LVNC (Figure 1B, Video 2), meeting both the Petersen (NCM/CM ratio=4.15) and Jacquier criteria (NCM mass=50.33%) and LVEF of 53.8%.

Global longitudinal strain was normal (GLS = -22%), with a slightly decreased basal and mid septal deformation, but with preserved apical deformation (Figure 1C). However, the MW analysis revealed the real dysfunctional myocardium. We found a decreased MWE, in addition to the septal segments, at the level of NC apical segments (Figure 1D-E), with an increased WW and a preserved CW in the posterior and lateral apical NC segments (Figure 1E).

In line with this findings, myocardial T1 mapping by CMR also showed the highest native T1 values in the apical segments up to 1180 ms (normal values 950 \pm 21 msec¹⁵), with substantial expanded extracellular volume of up to 35.1% (normal values 25 \pm 4%¹⁵), suggesting myocardial fibrosis. No areas of focal fibrosis have been identified with late gadolinium enhancement.

Bradycardia and the preserved LVEF limited the medical treatment. She was started on ACE inhibitors and low dose of diuretics. She was followed-up clinically every 6 months, with a favorable response to therapy and similar LVEF after 2 years.

CASE 2

A 71-year-old male, with history of HF, hypertension, dyslipidemia, paroxysmal atrial fibrillation, ische-

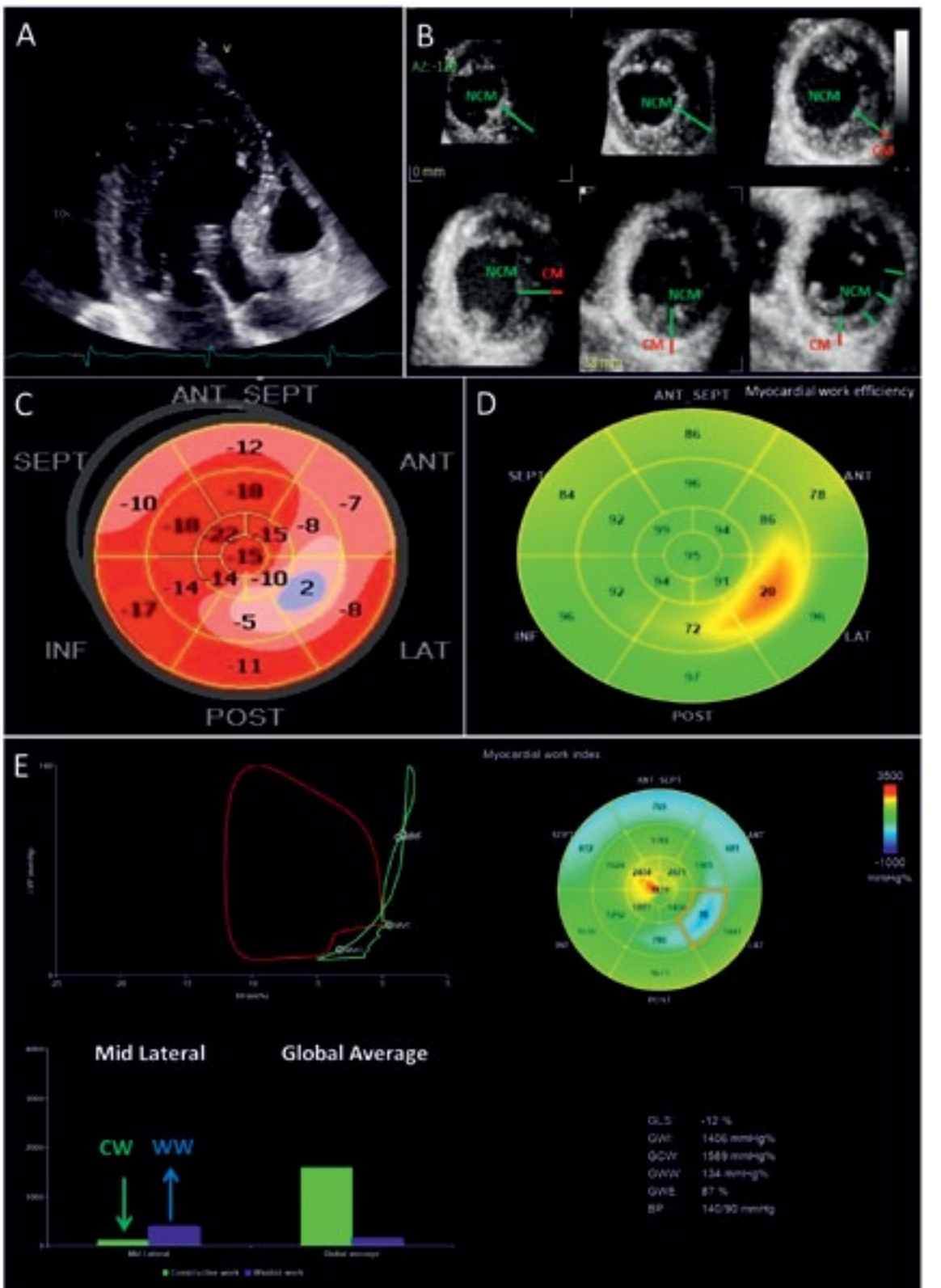
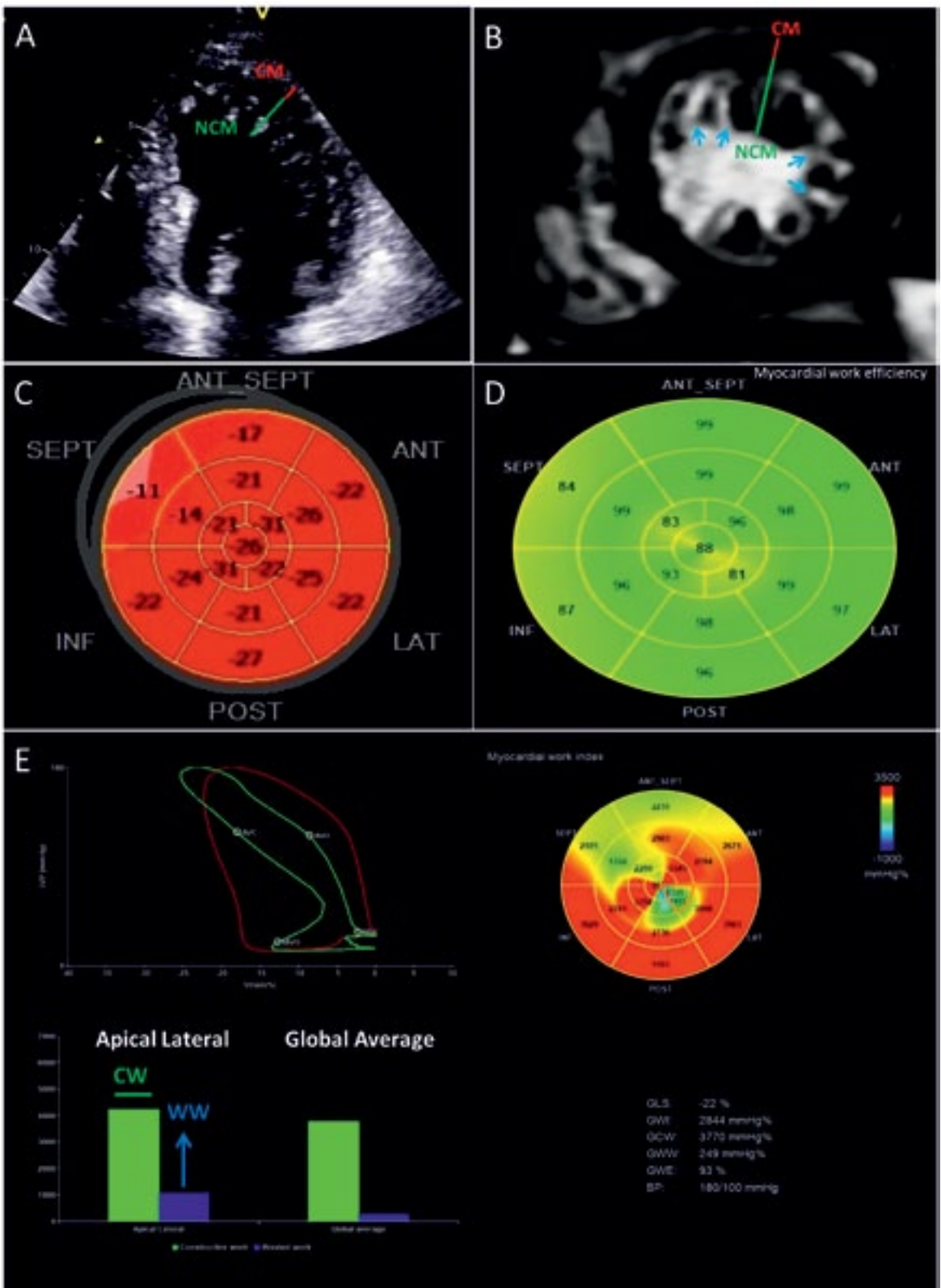
¹ „Carol Davila” University of Medicine and Pharmacy, Bucharest, Romania

² Department of Cardiology and Cardiovascular Surgery, Emergency University Hospital, Bucharest, Romania

³ Department of Radiology, Emergency University Hospital, Bucharest, Romania

► Contact address:

Roxana Cristina Rimbas MD, PhD, Department of Cardiology and Cardiovascular Surgery, Emergency University Hospital, 169 Splaiul Independentei, 050098, Bucharest, Romania.
E-mail: roxana.rimbas@umfcd.ro



mic stroke, chronic kidney disease (CKD), ankylosis spondylitis, and mild hypochromic normocytic anemia, presented with orthopnea and chest pain for about 2 months. Physical examination showed blood pressure of 140/90 mmHg, mitral systolic murmur grade II/VI, mild basal crackles and bilateral pedal edema. ECG revealed sinus rhythm with grade I atrioventricular block and major right bundle branch block. NTproBNP was severely elevated (>30000 pg/ml) with an increase of hs-cTnI up to 159 ng/l. 24-hour Holter ECG monitoring revealed also rare isolated PVC (79/24h) with short episodes of atrial fibrillation.

2D and 3D TTE showed LVEF of 38%, with diffuse hypokinesia, and a bilayered LV, with a sponge-like appearance of the endocardial layer due to the small interlacing trabeculae, with perfused intertrabecular recesses, suggestive for LVNC (Figure 2 A-B, Video 3-5). The NCM:CM ratio was 3.16. Mild mitral and aortic insufficiencies were also observed. GLS was significantly reduced to -12%, with significant deformation impairment, gradually from basal anterior and septal segments to mid apical posterior and lateral NC segments, in a „yin yang” pattern (Figure 2C), with corresponding significantly decreased MWE, increased WW and severely depressed CW, mainly in mid posterior and lateral NC segments (Figure 2 D-E). Coronarography did not revealed significant lesions. We did not perform a CMR evaluation, because of the CKD, and of the impossibility to maintain for a long time a stable position (ankylosis spondylitis). He was started on oral anticoagulants, beta-blockers, amiodarone, loop diuretics, ACE inhibitors and statins, with significant improvement of HF symptoms from NYHA class IV to NYHA class II.

DISCUSSION

Our cases illustrate the multimodality imaging findings in two different phenotypes of LVNC, with similar grades of NC, both symptomatic by HF, one with preserved and one with reduced LVEF. We also highlight the idea that in LVNC cardiomyopathy, LVEF does not depend only on the degree of NC, but also on the extension of functional changes in NC and C segments of the LV. As in the case of hypertrophic cardiomyopathy, it would be ideal to be able to distinguish at the first sight between a real LVNC cardiomyopathy and genetic or non-genetic phenocopies of myocardial hypertrabeculation.

LVNC is presumed to be a rare disorder of endomyocardial morphogenesis¹. However, acquired and potentially reversible hypertrabeculations of LV,

as forms of cardiac remodeling associated with other cardiomyopathies or other conditions with volume overload, raised questions regarding the role of epigenetic and hemodynamics factors, complicating the diagnosis of a true LVNC^{10,16,17}. The presence of hypertrabeculation fulfilling the LVNC criteria should be a starting point for clinical investigations. The next step should be the assessment of the functional impact and clinical implications, and then, if confirmed, to perform family screening and genetic testing. Multimodality imaging approach using 2D TTE, 3D TTE, STE with MW analysis, and CMR evaluation can solve the first two essential steps in the diagnosis of LVNC.

To better understand the functional implication of NC we need to look back at compaction process. It has been shown that this process gradually progresses from the epicardium to the endocardium, from the base to the apex and from the septum to the free wall in the LV¹⁸. The coronary circulation develops concurrently during this process, and the intertrabecular recesses are reduced to capillaries¹⁹. The timing of impairment determines the severity and extension of the LVNC, the LV apex being the most involved, as the compaction process concludes in the apex²⁰.

In line with all these findings, in both our patients, NC was predominant in mid-apical postero-lateral segments, with a reduced MWE in these segments, with a lower magnitude in the patient with preserved LVEF by comparison with the one with reduced LVEF. However, the cause of a reduced apical systolic performance in the first patient, with an apparently benign LVNC phenotype with preserved EF and normal GLS, could not have been clearly understood without using CMR and MW analysis by STE.

In our opinion, in the case with preserved LVEF, we found myocardial fibrosis detected by CMR at the level of NC segments, generating functional changes consisting only of an increased WW, without affecting CW. This finding suggests that LVNC with preserved LVEF is not just a normal and benign variant of LV hypertrabeculation. In patient with reduced LVEF, as we expected, we found significant deformation impairment and reduced MWE, with severely depressed CW and increased WW in NC segments, generating more important functional changes.

Chin et al.³ suggested that subendocardial perfusion defects might be present in LVNC, despite of the absence of epicardial coronary artery disease. These have also been described by Soler et al. using CMR²¹. Moreover, Junga et al.²² demonstrated, in a positron emission tomography (PET) study, restricted myocar-

dial perfusion and decreased coronary flow reserve (CFR) in areas of LVNC, which may be related to failure of the coronary microcirculation to grow with the increasing ventricular mass. An impaired CFR leads to the development of small areas of necrosis and replacement fibrosis, providing an arrhythmogenic substrate. Moreover, De Melo et al.²³ recently evaluated myocardial perfusion and metabolism, by using 18F-fluoro-2-deoxyglucose dynamic PET (FDG-PET) and ^{99m}Tc sestamibi single-photon emission computed tomography (SPECT), and found out that LVNC was associated with a diffuse reduction in myocardial glucose metabolism, with a negative correlation between myocardial glucose uptake (MGU) and NCM:CM ratio, suggesting a worse LV remodeling over time in patients with higher NCM:CM ratios. Based on these findings, they suggested a different pathophysiology of LVNC, by comparison with other cardiomyopathies, in which higher rates of MGU have been observed. More precisely, they suspected a mitochondrial dysfunction pathway, which has been recently showed to exacerbate the biogenesis and development of fibrosis²⁴.

All these findings might explain why CMR evaluation with myocardial T1 mapping showed higher native T1 values and ECV in the apical NC segments in our patient, suggesting myocardial fibrosis, which led to secondary reduced apical systolic performance.

CONCLUSIONS

Our cases highlights that multimodality imaging by 2D echocardiography with speckle tracking and myocardial work analysis, 3D echocardiography, and CMR with T1 mapping can define functional criteria into a future stepwise diagnostic algorithm in LVNC, confirming impairment of non-compacted segments, by decreasing work efficiency due to the progressive increase of wasted work from the early stages and the decrease of the constructive work in the late stages, on the background of myocardial fibrosis.

It also emphasis that multimodality imaging can discern between benign hypertrabeculation and LVNC cardiomyopathy with preserved EF, showing reduced systolic performance and incipient myocardial fibrosis in non-compacted segments, despite normal deformation.

Conflict of interest: none declared.

***Watch the full videos on:**

<https://www.youtube.com/playlist?list=PLa8QmtbIW6riLkNUMlZqHDFLGLRXtGsuF>



References:

1. Maron BJ, Towbin JA, Thiene G, Antzelevitch C, Corrado D, Arnett D, Moss AJ, Seidman CE, Young JB. Contemporary definitions and classification of the cardiomyopathies: An American Heart Association Scientific Statement from the Council on Clinical Cardiology, Heart Failure and Transplantation Committee; Quality of Care and Outcomes Research and Function. *Circulation* 2006; 113: 1807–1816.
2. Elliott P, Andersson B, Arbustini E, Bilinska Z, Cecchi F, Charron P, Dubourg O, Kühn U, Maisch B, McKenna WJ, Monserrat L, Panikvar S, Rapezzi C, Seferovic P, Tavazzi L, Keren A. Classification of the cardiomyopathies: A position statement from the European society of cardiology working group on myocardial and pericardial diseases. *Eur. Heart J* 2008; 29: 270–276.
3. Chin TK, Perloff JK, Williams RG, Jue K, Mohrmann R. Isolated non-compaction of left ventricular myocardium. A study of eight cases. *Circulation* 1990; 82: 507–513.
4. Jenni R, Oechslin E, Schneider J, Attenhofer Jost C, Kaufmann PA. Echocardiographic and pathoanatomical characteristics of isolated left ventricular non-compaction: A step towards classification as a distinct cardiomyopathy. *Heart* 2001; 86: 666–671.
5. Stöllberger C, Gerecke B, Finsterer J, Engberding R. Refinement of echocardiographic criteria for left ventricular noncompaction. *Int. J. Cardiol* 2013; 165:463–467.
6. Petersen SE, Selvanayagam JB, Wiesmann F, Robson MD, Francis JM, Anderson RH, Watkins H, Neubauer S. Left ventricular non-compaction: Insights from cardiovascular magnetic resonance imaging. *J. Am. Coll. Cardiol* 2005; 46: 101–105.
7. Jacquier A, Thuny F, Jop B, Giorgi R, Cohen F, Gaubert JY, Vidal V, Bartooli JM, Habib G, Moulin G. Measurement of trabeculated left ventricular mass using cardiac magnetic resonance imaging in the diagnosis of left ventricular non-compaction. *Eur. Heart J*. 2010; 31: 1098–1104.
8. Di Toro A, Giuliani L, Smirnova A, Favalli V, Serio A, Urtis M, Grasso M, Arbustini E. Myths to debunk: the non-compacted myocardium. *Eur. Heart J. Suppl.* 2020; 22: L6–L10.
9. Towbin JA, Lorts A, Jefferies JL. Left ventricular non-compaction cardiomyopathy. *Lancet* 2015; 386: 813–825.
10. Wengrofsky P, Armenia C, Oleszak F, Kupferstein E, Rednam C, Mitre CA, McFarlane SI. Left Ventricular Trabeculation and Non-compaction Cardiomyopathy: A Review. *EC Clin. Exp. Anat.* 2019; 2: 267–283.
11. Chan J, Edwards NFA, Khandheria BK, Shiino K, Sabapathy S, Anderson B, Chamberlain R, Scalia GM. A new approach to assess myocardial work by non-invasive left ventricular pressure-strain relations in hypertension and dilated cardiomyopathy. *Eur. Heart J. Cardiovasc. Imaging* 2019; 20:31–39.
12. Galli E., Leclercq C, Hubert A, Bernard A, Smiseth OA, Mabo P, Samset E, Hernandez A, Donal E. Role of myocardial constructive work in the identification of responders to CRT. *Eur. Heart J. Cardiovasc. Imaging* 2018; 19:1010–1018.
13. Boe E, Russell K, Eek C, Eriksen M, Remme EW, Smiseth OA, Skulstad H. Non-invasive myocardial work index identifies acute coronary occlusion in patients with non-STsegment elevation-acute coronary syndrome. *Eur. Heart J. Cardiovasc. Imaging* 2015; 16:1247–1255.
14. Clemmensen TS, Eiskjaer H, Ladefoged B, Mikkelsen F, Sorensen J, Granstam SO, Rosengren S, Flachskampf FA, Poulsen SH. Prognostic implications of left ventricular myocardial work indices in cardiac amyloidosis. *Eur. Heart J. Cardiovasc. Imaging* 2020; 0:1–10.

15. Dabir D, Child N, Kalra A, Rogers T, Gebker R, Jabbour A, Plein S, Yu CY, Otton J, Kidambi A, McDiarmid A, Broadbent D, Higgins DM, Schnackenburg B, Foote L, Cummins C, Nagel E, Puntmann VO. Reference values for healthy human myocardium using a T1 mapping methodology: results from the International T1 Multicenter cardiovascular magnetic resonance study. *J. Cardiovasc. Magn. Reson.* 2014; 16: 69.
16. Floria M, Tinica G, Grecu M. Left ventricular non-compaction - challenges and controversies. *Maedica.* 2014; 9: 282–288.
17. Rugina M, Predescu LM, Salagean M, Coman IM, Bubenek-Turconi S. Left ventricular noncompaction. *Romanian Journal of Cardiology.* 2013; 23: 1-6.
18. Sedmera D, Pexieder T, Vuillemin M, Thompson RP, Anderson RH. Developmental patterning of the myocardium. *Anat. Rec.* 2000; 258: 319–337.
19. Ritter M, Oechslin E, Sütsch G, Attenhofer C, Schneider J, Jenni R. Isolated noncompaction of the myocardium in adults. *Mayo Clin. Proc.* 1997; 72: 26–31.
20. Oechslin E, Jenni R. Left ventricular non-compaction revisited: A distinct phenotype with genetic heterogeneity? *Eur. Heart J.* 2011; 32: 1446–1456.
21. Soler R, Rodríguez E, Monserrat L, AlvarezN. MRI of subendocardial perfusion deficits in isolated left ventricular noncompaction. *J. Comput. Assist. Tomogr.* 2002; 26: 373–375.
22. Junga G, Kneifel S, Von Smekal A, Steinert H, Bauersfeld U. Myocardial ischaemia in children with isolated ventricular non-compaction. *Eur. Heart J.* 1999; 20: 910–916.
23. Tavares de Melo MD, Pinto Giorgi MC, Assuncao AN Jr, Dantas RN Jr, de Arimateia Araujo Filho J, Parga Filho JR, de Souza Bierrenbach AL, de Lima CR, Soares J Jr, Meneguetti JC, Mady C, Hajjar LA, Kalil Filho R, Bocchi EA, Cury Salemi VM. Decreased glycolytic metabolism in non-compaction cardiomyopathy by 18F-fluoro-2-deoxyglucose positron emission tomography: New insights into pathophysiological mechanisms and clinical implications. *Eur. Heart J. Cardiovasc. Imaging* 2017; 18: 915–921.
24. Li X, Zhang W, Cao Q, Wang Z, Zhao M, Xu L, Zhuang Q. Mitochondrial dysfunction in fibrotic diseases. *Cell Death Discov.* 2020; 6: 80.