

CASE PRESENTATION

Rare association of acute pulmonary embolism and type B aortic dissection: anticoagulant therapeutic dilemma

Ovidiu Mitu^{1,2}, Radu Miftode^{1,2}, Adrian Pintilie², Antoniu Octavian Petris^{1,2}

Abstract: We report the case of an 88-year-old male who was admitted for presenting acute onset pain in the right lower limb associated with dyspnea. After clinical exam and Doppler echography, the deep vein thrombosis was confirmed. The thoracic angio computed tomography revealed segmentary pulmonary embolism, but also showed aneurysmal dilated ascending aorta and presence of chronic extensive type B aortic dissection with multiple atheroma plaques. Despite the unfortunate association, the anticoagulant treatment was carefully monitored, with no complications or bleeding events. Taking into consideration the thromboembolic event and high atherosclerotic burden, the patient was discharged with novel oral anticoagulant and statin, abstaining from antiaggregant therapy. The association of pulmonary embolism with aortic dissection represents a rare condition that raises certain anticoagulant and therapeutic dilemma.

Keywords: pulmonary embolism, aortic dissection, venous thromboembolism, deep vein thrombosis, anticoagulation.

Rezumat: Pacient în vârstă de 88 ani, sex masculin, a fost internat pentru debutul acut al durerilor la nivelul membrului inferior drept, însoțite de dispnee. Tromboza venoasă profundă a fost confirmată pe baza examenului clinic și a ecografiei Doppler. Examinarea angioCT toracic a evidențiat embolie pulmonară segmentară dar și dilatare aneurismală de aortă ascendentă și prezența unei disecții aortice cronice tip B extensive cu multiple plăci de aterom. În ciuda asocierii nefaste, tratamentul anticoagulant a fost atent monitorizat, fără complicații sau evenimente hemoragice. Datorită evenimentului tromboembolic și încărcăturii aterosclerotice importante, pacientul a fost externat cu anticoagulant oral direct și statină, fără medicație antiagregantă. Asocierea emboliei pulmonare cu disecția de aortă reprezintă o situație rară care ridică dileme certe terapeutice.

Cuvinte cheie: embolie pulmonară, disecție de aorta, tromboembolism venos, tromboză venoasă profundă, anticoagulare.

INTRODUCTION

Treatment of pulmonary embolism consists in full dose anticoagulation or even thrombolysis that are associated with high bleeding risk. The presence of aortic dissection in a patient usually represents a contraindication or at least a major precaution for anticoagulant treatment. Nonetheless, the concomitant association of both pathologies is rare but raises specific therapeutic dilemmas.

CASE REPORT

We present the case of an 88-year old male, hypertensive, former smoker, who was admitted to the cardiology clinic for acute onset pain in the right lower limb associated with recent dyspnea.

His past medical history consisted of previous diagnosis of chronic obstructive pulmonary disease (COPD) GOLD I stage, chronic kidney disease stage 3 and arterial hypertension stage 2 for which the patient received bisoprolol and amlodipine in moderate doses. Clinical examination revealed: obesity grade I (body mass index 31 kg/m²), regular cardiac sounds, blood pressure (BP) 140/80 mmHg, 92 bpm, spontaneous oxygen saturation 88%, mild edema and warmer right lower limb.

Biochemical results showed: normal full blood count, mild dyslipidemia (LDL cholesterol 140 mg/dl), moderate renal function impairment (creatinine clearance 54 ml/min/1.73m²), hepatic function and coagulation in normal ranges. NTproBNP was slightly ele-

¹ „Grigore T. Popa” University of Medicine and Pharmacy, Iasi, Romania

² „St. Spiridon” Clinical Emergency Hospital, Iasi, Romania

► Contact address:

Radu Miftode, MD

„St. Spiridon” Hospital, 1st Independentei Street, Iasi, Romania.

E-mail: radu.miftode@yahoo.com

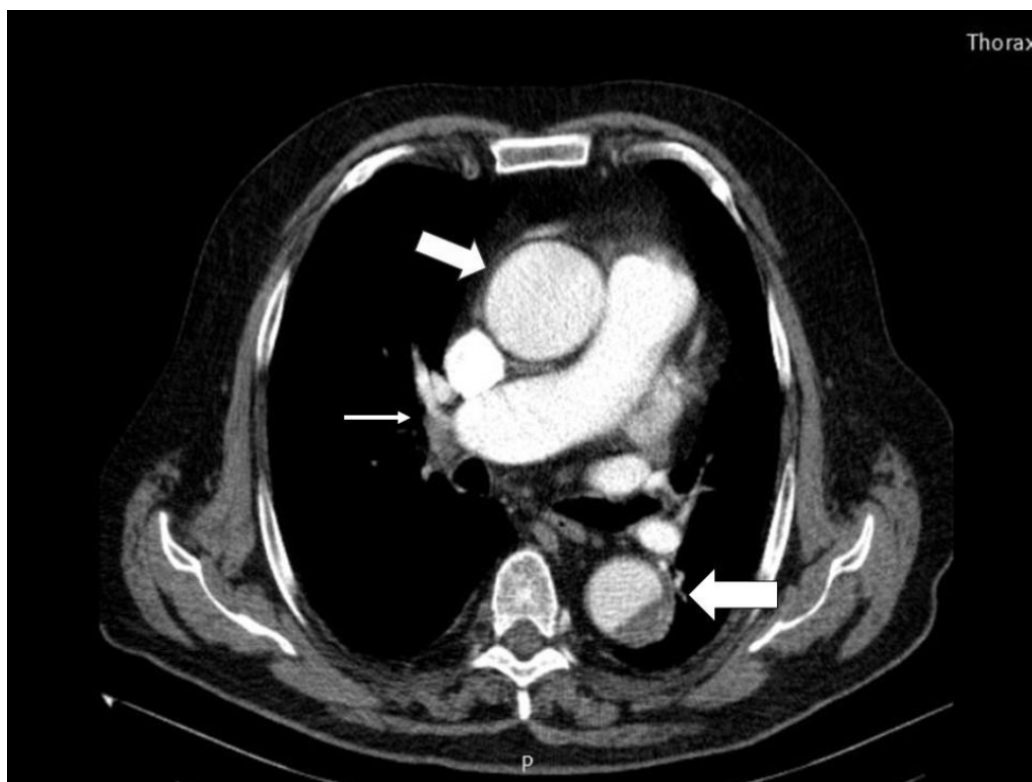


Figure 1. Thoracic angio CT: Right segmentary pulmonary embolism (white arrow), respectively dilated ascending aorta and descending aortic dissection (white lines).

vated (924 pg/ml) while D-dimer value was very high (>5 µg/ml).

The patient presented on admission electrocardiogram sinus tachycardia 100 bpm, with frequent supraventricular premature beats. Transthoracic echocardiography revealed: non-dilated cardiac cavities, left ventricular ejection fraction 50%, flattened movement of interventricular septum, TAPSE 18 mm, dilated inferior vena cava with diminished collapse, ascendant aorta dilated (46 mm) with atheromatosis.

An emergency venous Doppler echography was performed and confirmed the presence of occlusive echogenic material in the right common, superficial and profound femoral vein and partial occlusive in the popliteal vein, all non-compressible and with absence of Doppler signal – highly typical aspect for recent thrombus.

Taking into consideration the clinical presentation, the presence of acute deep vein thrombosis, increased specific biochemical markers and echocardiographic aspects, a pulmonary angio computed tomography (CT) was indicated. The angio CT confirmed partial thrombosis of the right medial, lateral and posterior segmentary pulmonary arteries, the main pulmonary arteries being permeable. Moreover, the CT also re-

vealed aneurysmal dilated ascending aorta (54/45 mm), mild parietal thrombosis of the aortic arch and important thrombosis of the descendent aorta – suggestive for a chronic type B aortic dissection, along with multiple aortic plaques (Figures 1, 2).

After image confirmation of acute pulmonary embolism and deep vein thrombosis, the anticoagulation treatment had to be the treatment of choice but the association of descendent aortic dissection was a major precaution for anticoagulation. However, by computing the simplified Pulmonary Embolism Severity Index (PESI) score, the patient was at high risk (age, COPD and SaO₂). Thus, the decision was in favor for starting anticoagulation therapy with unfractionated heparin under strict monitorization of aPTT. Statin therapy was as well introduced taking into consideration the high atherosclerotic burden but abstained from introducing the antiplatelet therapy. During hospitalization, the patient also developed paroxysmal fast-rhythm atrial fibrillation that responded to amiodarone loading. The clinical evolution was favorable, the lower limb inflammation diminished, the BP was maintained around 120/80 mmHg and heart rate was slightly higher, 70-80 bpm, despite treatment with diltiazem associated with amiodarone. The medication at

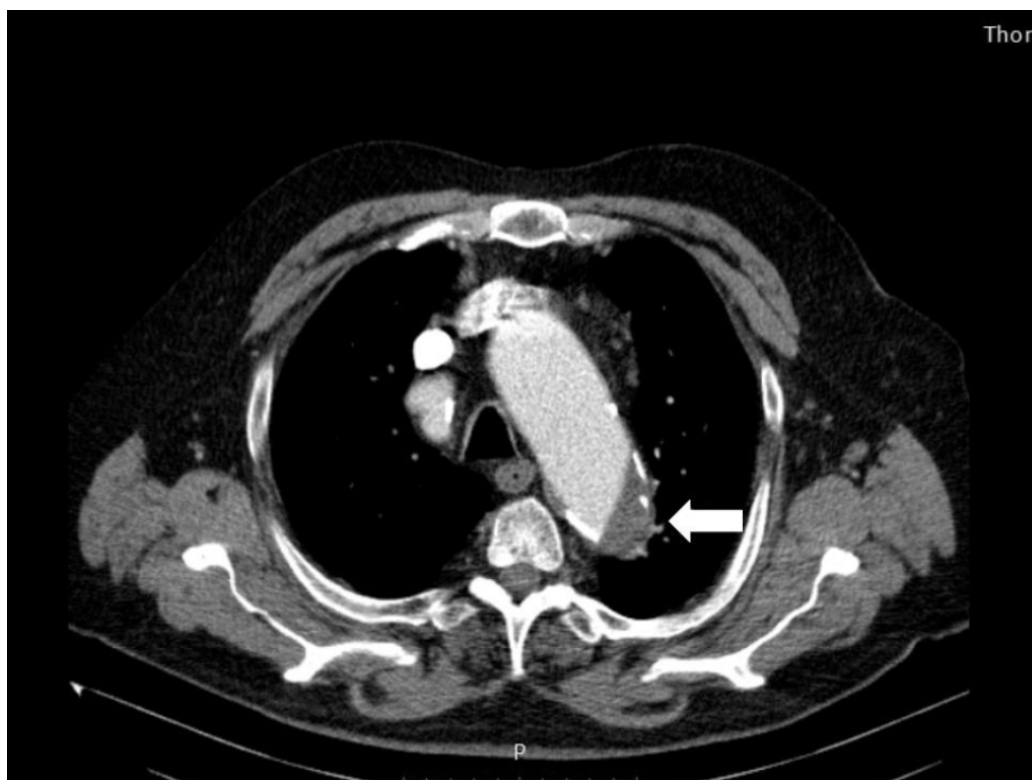

Figure 2. Thoracic angio CT: beginning of aortic dissection from the distal part of the aortic arch (white line) along with multiple calcified atheroma plaques.

discharge consisted in: low regime of novel oral anti-coagulant (apixaban 2.5 mg bid), diltiazem, amiodarone in prophylactic dose, high statin dose (rosuvastatin 20 mg daily), angiotensin converting enzyme inhibitor and oral venous trophic. One dilemma was for introducing aspirin for the high atherosclerotic burden but taking into consideration the age, the acute thromboembolic pathology and the need for chronic anticoagulant, we decided to postpone the administration of aspirin in prophylactic dose.

DISCUSSION

Type A aortic dissection still represents a devastating aortic pathology, with high mortality rates even in surgical treated patients. On the other hand, patients with type B aortic dissection managed medical have the lowest mortality rates. Previous atherosclerosis, along with other risk factors, is a key factor for developing this disease since inflammation and extracellular matrix degradation lead to remodeling of the aortic wall structure¹.

The association of acute pulmonary embolism and type B aortic dissection is rare and the preferred management should be based on the predominant symptomatology. However, due to anticoagulant treatment

for venous thromboembolism, the aortic pathology may evolve leading to bleeding local complications that have been treated with thoracic endovascular aortic repair (TEVAR)^{2,3}. In other situations, non-dissecting ascending aortic aneurysm or, infrequently, type A aortic dissection can mimic pulmonary embolism by subsequent compression and possibly occlusion, leading to diagnostic and treatment confusion^{4,5}.

There are still uncertainties regarding the association of aortic pathology and venous thromboembolic manifestations. A recent retrospective study demonstrated that aortic aneurysm surgery was associated with an increased risk of venous thromboembolism within 6-months post-operation. However, the mechanisms underlying this association remain unclear⁶. Another study reported no evidence for sustaining the use of anticoagulant therapy for deep vein thrombosis prophylaxis in patients undergoing abdominal aortic surgery⁷.

In our case, the patient presented for highly suggestive venous thromboembolism manifestations that was confirmed through pulmonary angio CT, but the aortic dissection was a fortuit discovery. Fortunately, the evolution was favorable, with no bleeding complications developed under anticoagulant thera-

py and the treatment for both pathologies remained conservative. Though the theoretical study doses for apixaban in pulmonary embolism patients in the first months is 5 mg bid⁸, we preferred the 2.5 mg bid dose for chronic surveillance taking into account the age and the renal disease. Another anticoagulant option could have been the vitamin K antagonists but due to the high INR variability and the impossibility of the patient for a close INR check-up we also preferred apixaban. Moreover, another limitation for a higher anticoagulant dosage was represented by the presence of the aortic disease. Nonetheless, the patient will remain under strict surveillance since the anticoagulant is mandatory but could affect the aortic pathology leading to several complications that may require in the future TEVAR or surgery. A close follow-up of the patient was scheduled for evaluation of the anticoagulant therapy, as well as imagistic monitoring for the progression of the aneurysmal dilated ascending aorta and aortic dissection.

CONCLUSION

The association of pulmonary embolism and aortic dissection remains uncommon, especially in emergency situations. The main therapeutic problem is the use of anticoagulant with maximal benefit but, meanwhile,

trying to minimize the increased bleeding risk. Management of such patients represents a continuous challenge in everyday clinical practice.

Conflicts of interest: none declared.

References

1. Gawinecka J, Schönraht F, von Eckardstein A. Acute aortic dissection: pathogenesis, risk factors and diagnosis. *Swiss Med Wkly.* 2017; 147:w14489.
2. Chai DZ, Zhang HY, Zhang F. Pulmonary Embolism and Stanford Type B Aortic Dissection in the Same Patient. *J Vasc Med Surg* 2015; 3:6.
3. Al-Zuabi S, Varkey AP, Abdalmaksoud SF et al. A rare case of leaking thoracic aortic aneurysm in a patient with massive pulmonary embolism. *Egypt J Intern Med* 2013; 25: 47–50.
4. Bhatt K, Navia J, Flamm S, Bolen M. Type A aortic dissection mimicking a saddle pulmonary embolus on computed tomographic angiography. *Circulation* 2014; 129(21):2180-2182.
5. Halefoglu AM. CT Diagnosis of a Thoracic Aort Aneurysm with Type B Aortic Dissection Clinically Misdiagnosed as Acute Pulmonary Embolism. *Case Rep Med.* 2012; 2012:720394.
6. Lee F-Y, Chen W-K, Chiu C-H et al. Increased risk of deep vein thrombosis and pulmonary thromboembolism in patients with aortic aneurysms: A nationwide cohort study. *PLoS ONE* 2017; 12(6): e0178587.
7. Bani-Hani MG, Al-Khaffaf H, Titi MA, Jaradat I. Interventions for preventing venous thromboembolism following abdominal aortic surgery. *Cochrane Database Syst Rev.* 2008; (1):CD005509.
8. Liu X, Johnson M, Mardekian J et al. Apixaban Reduces Hospitalizations in Patients With Venous Thromboembolism: An Analysis of the Apixaban for the Initial Management of Pulmonary Embolism and Deep-Vein Thrombosis as First-Line Therapy (AMPLIFY) Trial. *J Am Heart Assoc.* 2015; 4(12).